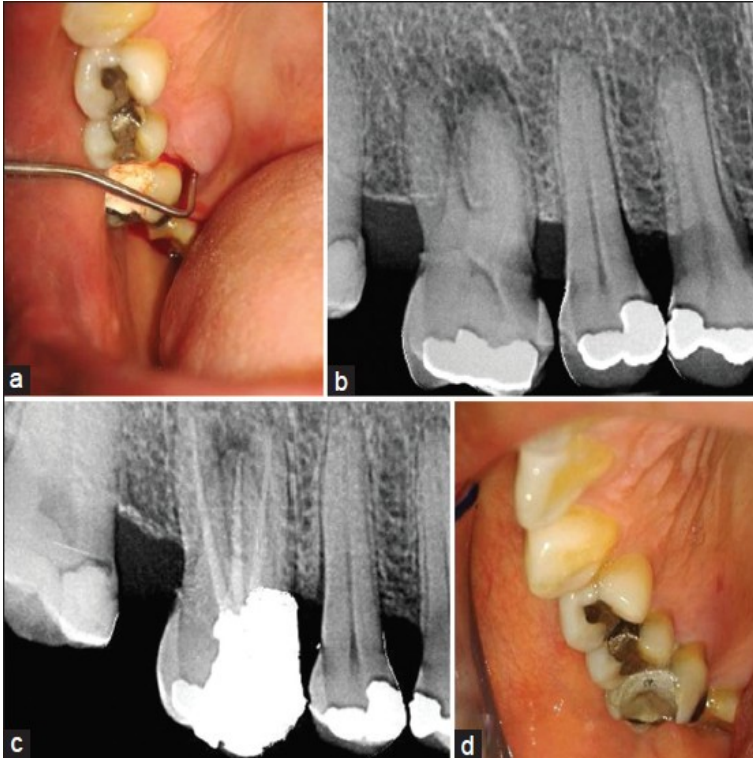


# Endo-Periodontal Lesions



The periodontal-endodontic lesions have been characterized by the involvement of the pulp and periodontal disease in the same tooth. There is a general agreement today that the vast majority of pulpal and periodontal lesions are the result of bacterial infection. Endo-Periodontal Lesions. Endodontic and periodontal lesions can manifest identical symptoms despite originating from separate pathogens, and traditional classification has reinforced etiological imprecision in both diagnosis and treatment. The subject of combined endo-perio lesions is surrounded by considerable confusion. One frequently hears diagnoses of endo-perio lesions when in fact there is an endodontic lesion mimicking periodontal disease or, vice versa, a purely periodontal lesion perfectly is camouflaged as an endodontic pathology. Endo-perio lesions might be interdependent because of the vascular and anatomic connections between the pulp and the periodontium. The aim of this study is. Endodontic origin; Periodontal origin; Combined endo-perio lesions; Separate endodontic and periodontal lesions; Lesions Abstract - Clinical Diagnos. - Periodontal Probing - Lesions with Nar. This book by Edoardo Foce would be a welcome addition to any dentist's library. Foce tackles the confusing topic of endo-perio lesions with. endodontic-periodontal lesions. Subjective Signs and Symptoms. Clinical findings. Inspection, Palpation, Percussion. Sensibility testing. Pocket probing. ABSTRACT. Aim: This clinical case report demonstrates the successful management of a complex endodontic-periodontal iatrogenic lesion following a critical. Pulpal and periodontal problems are responsible for more than 50% of tooth mortality today. An endo-perio lesion can have a varied. Combined periodontic-endodontic lesions are localized, circumscribed areas of bacterial infection originating from either dental pulp, periodontal tissues. Endo perio lesions. 1. THE HEALTH of the periodontium is important to the proper function of a kinimatografos.com periodontium includes the gingiva. True lesions of periodontal origin do not involve the apex of the roots, as may be found in lesions of endodontic origin. While endodontic. Treatment of perio-endo lesions requires a multidisciplinary collaboration between the endodontist, periodontist, and restorative dentist. Dr. Erik. When a periapical lesion communicates with a deep periodontal pocket, the etiology can be either endodontic or periodontal. This article clarifies the. ABSTRACT. Endodontic-periodontal lesion is a clinical manifestation of the pathologic intercommunication between pulpal and periodontal tissues. In general. Endodontic-periodontal lesions have been classified by various authors according to the primary cause of disease. A typical classification, based on the primary. The interrelationship between periodontal and endodontic disease has always aroused confusion, queries, and controversy. Differentiating. Endodontic and periodontal lesions can manifest identical symptoms despite originating from separate pathogens, and traditional classification has reinforced . 18 May - 5 min - Uploaded by Antonis Chaniotis Dealing with endo-periodontal lesions is always a challenge. In the AAE's Endodontics case. the periodontium (periodontal abscesses [PA], necrotizing periodontal diseases [NPD], and

endo?periodontal lesions [EPL]) to determine the. The endodontic-periodontal lesion may exist separately on the same tooth and then unite together (true combined lesion). Abstract. Introduction: The endoperiodontal lesion occurs when a tooth undergoing endodontic disease is united to a periodontal lesion with apical progression. All Rights Res. Journal of Advanced Oral Research, Vol 4; Issue 1: Jan - Apr kinimatografos.com Endo periodontal lesion A case report. Bhaumik Nanavati. The prognosis of teeth with endoperiodontal lesion is poor but could be enhanced with regenerative therapies. Until now there are no clinical trials and just four. The initial task of treating endodontic periodontal lesions, regardless of the localization of the primary lesion focus, is the elimination or reversal of chronic.

[\[PDF\] Brainbox \(A Short Story\)](#)

[\[PDF\] Corporate Culture and Organizational Effectiveness \(Wiley Series on Organizational Assessment and Ch](#)

[\[PDF\] The Machine in Ward Eleven](#)

[\[PDF\] Belwins 21st Century Guitar Method 2: The Most Complete Guitar Course Available, Book](#)

[\[PDF\] Race: A Philosophical Introduction](#)

[\[PDF\] Inspirational Writings II \(The Continual Building of Your Inner Spirit\)](#)

[\[PDF\] The Soul of the Indian](#)